

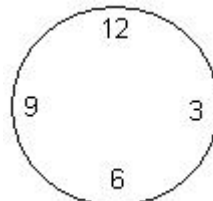
Current Assessment: 12/29/2010 3:44:29 PM

Wound Start Date: 12/23/2010

Site: Chin- 873.59
 Stage: Stage 2
 Length: 0.2cm
 Width: 0.7cm
 Depth: 0cm
 Pain Index: None
 Peri Wound: Pink
 Odor: No
 Bed Description: Granulation
 Bed Percentage: 100
 Bed Description:
 Bed Percentage:
 Exudate Type: None
 Exudate Amount: None
 Wound Edge: Attached
 Obtained Off-Site: No
 Undermining: No
 Tunneling: No
 Debridement Date:

Current Treatment

Frequency: QD/PRN - Daily
 Prep: Cleanse with normal saline
 Primary: Cover wound with Aquacel® AG 2 x 2 - 7
 Secondary: Cover wound with Allevyn* Adhesive - 5 x 5
 Border - 7
 Heel Hover
 Pressure
 Redistribution:
 Prevention Action: Antifungal Cream - TID



Signature: _____

Skin Integrity Progress Notes

12/29/2010 3:44:29 PM mikes

Wound still looks good will continue treatment until next assessment at which time the MD will make a dressing order change

Change from last assessment: (Better) (Worse) (No Change)

Wound History

Date	12/29/2010 3:43:15 PM	12/29/2010 3:41:44 PM	12/29/2010 3:41:01 PM	12/29/2010 3:36:34 PM
Stage	Stage 2	Stage 2	Stage 2	Stage 2
Length	0.6cm	0.6cm	1cm	1cm
Width	2cm	2cm	1cm	1cm
Depth	0cm	0cm	1cm	1cm
Pain	4	4	4	4
Peri	Pink	Pink	Pink	Pink
Odor	No	No	No	No
Wound Bed	Granulation	Granulation	Granulation	Granulation
Bed Percentage	100	100	100	100
Wound Bed				
Bed Percentage				
Exudate Type	Serosanguineous	Serosanguineous	Serosanguineous	Serosanguineous
Exudate Amount	Moderate	Moderate	Moderate	Moderate
Wound Edge	Inflamed	Inflamed	Inflamed	Inflamed
Obtained Off-Site	No	No	No	No
Undermining	No	No	No	No
Tunneling	No	No	No	No
Debridement Date				

Treatment History

Date	12/29/2010 3:43:43 PM	12/29/2010 3:41:14 PM	12/29/2010 3:37:56 PM	12/29/2010 12:54:13 PM
Frequency	QD/PRN - Daily	QD/PRN - Daily	QD/PRN - Daily	QD/PRN - Daily
Wound Preparation	Cleanse with normal saline	Cleanse with normal saline	Cleanse with normal saline	Cleanse with normal saline
Primary Dressing	Cover wound with Aquacel® AG 2 x 2	Cover wound with Aquacel® AG 2 x 2	Cover wound with Aquacel® AG 2 x 2	Cover wound with Aquacel® AG 2 x 2
Secondary Dressing	Cover wound with Allevyn* Adhesive - 5 x 5 Border - 7	Cover wound with Allevyn* Adhesive - 5 x 5 Border - 7	Cover wound with Allevyn* Adhesive - 5 x 5 Border - 7	Cover wound with Allevyn* Adhesive - 5 x 5 Border - 7
Pressure Redistribution	Heel Hover	Heel Hover	Heel Hover	Heel Hover
Preventative Action	Antifungal Cream - TID	Antifungal Cream - TID	Antifungal Cream - TID	Antifungal Cream - TID

Note History

12/29/2010 3:43:15 PM	mikes	This wound looks much better and has been healing nicely. Will continue same treatment for the next week and may d/c after next MD assessment.
12/29/2010 3:41:44 PM	mikes	This wound looks much better and has been healing nicely. Will continue same treatment for the next week and may d/c after next MD assessment.
12/29/2010 3:41:01 PM	mikes	Wound still looks good will continue treatment until next assessment at which time the MD will make a dressing order change
12/29/2010 3:36:34 PM	mikes	This wound looks much better and has been healing nicely. Will continue same treatment for the next week and may d/c after next MD assessment.